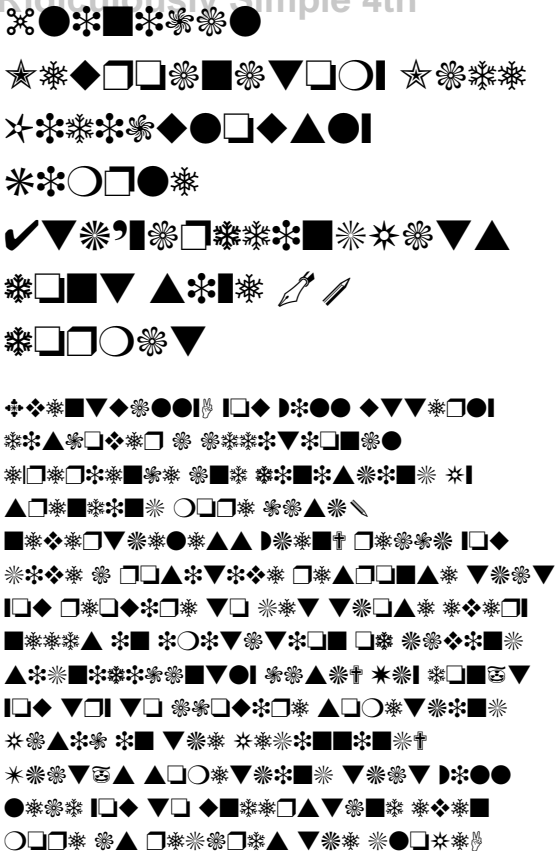




Access Free Clinical Neuroanatomy Made Ridiculously Simple 4th






Access Free Clinical Neuroanatomy Made Ridiculously Simple 4th





Access Free Clinical Neuroanatomy Made Ridiculously Simple 4th





Access Free Clinical Neuroanatomy Made Ridiculously Simple 4th



Access Free Clinical Neuroanatomy Made Ridiculously Simple 4th





Access Free Clinical Neuroanatomy Made Ridiculously Simple 4th






Access Free Clinical Neuroanatomy Made



Ridiculously Simple 4th



Access Free Clinical Neuroanatomy Made Ridiculously Simple 4th



Access Free Clinical Neuroanatomy Made Ridiculously Simple 4th



Access Free Clinical Neuroanatomy Made Ridiculously Simple 4th

